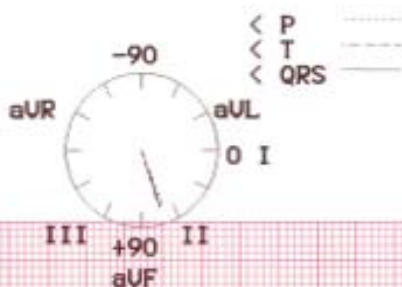


Measurement Results:

QRS		96	ms
QT/QTcB	326 /	359	ms
PR		124	ms
P		94	ms
RR/PP	800 /	820	ms
P/QRS/T	68/ 71/	72	degrees

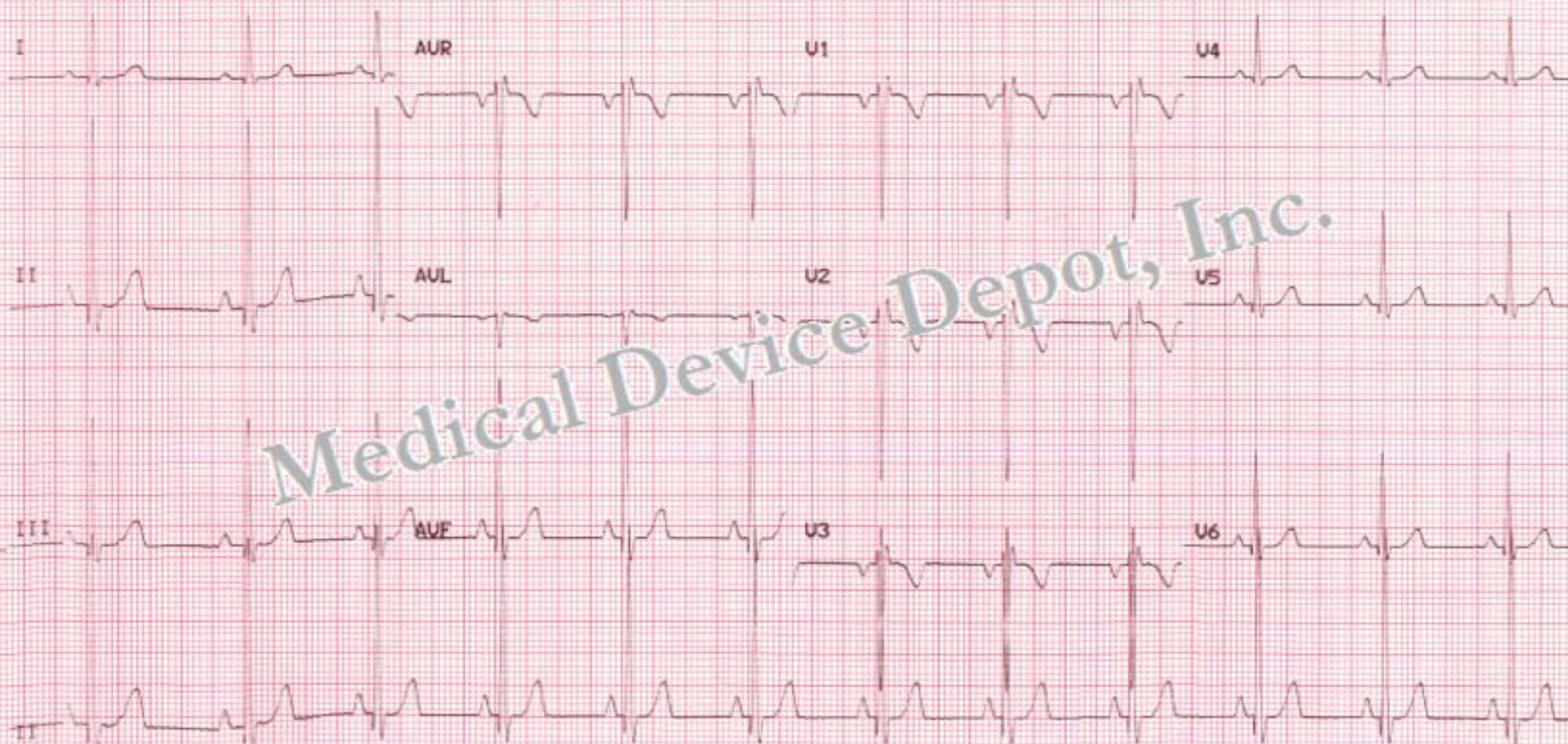


Interpretation:

12SL - Interpretation:
 Sinus rhythm with sinus arrhythmia
 Batrial enlargement
 Incomplete right bundle branch block
 Left ventricular hypertrophy
 ST & T wave abnormality, consider anterior ischemia
 Abnormal ECG

Order Physician :
 Technician :

Unconfirmed report.



Medical Device Depot, Inc.